

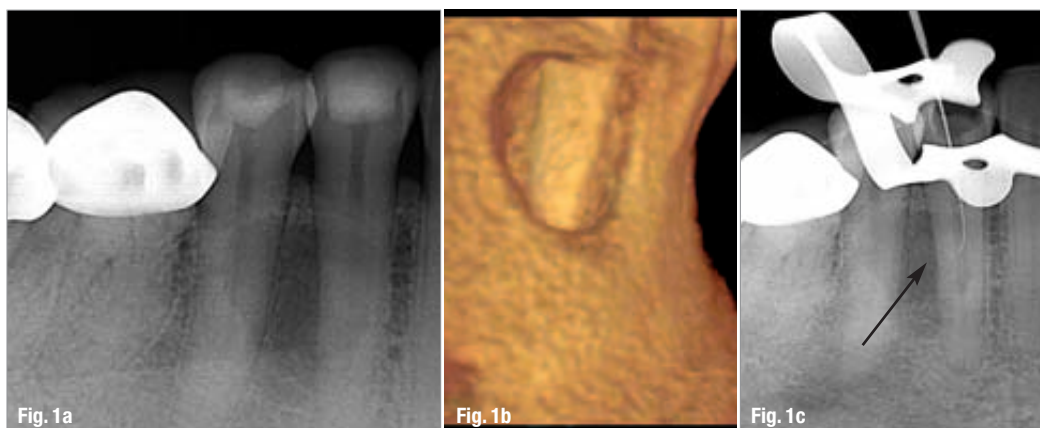
# Endodontic success: The pursuit of our potential

Author\_ Dr Wyatt D. Simons, USA

**Fig. 1a**\_A mid-root, cystic-appearing radio-lucency was noted without peri-apical involvement.

**Fig. 1b**\_Upon CBCT evaluation, a lateral portal of exit can be visualised in the centre of this mid-root radio-lucency. This aided in the diagnosis of disease of endodontic origin and furthered the success of treatment.

**Fig. 1c**\_Lateral system instrumented with a sharp J-curve of a stiff #15 hand file.



**Fig. 2a**\_When the cyst was surgically removed, the mid-root lateral was noted to be sealed with gutta-percha.

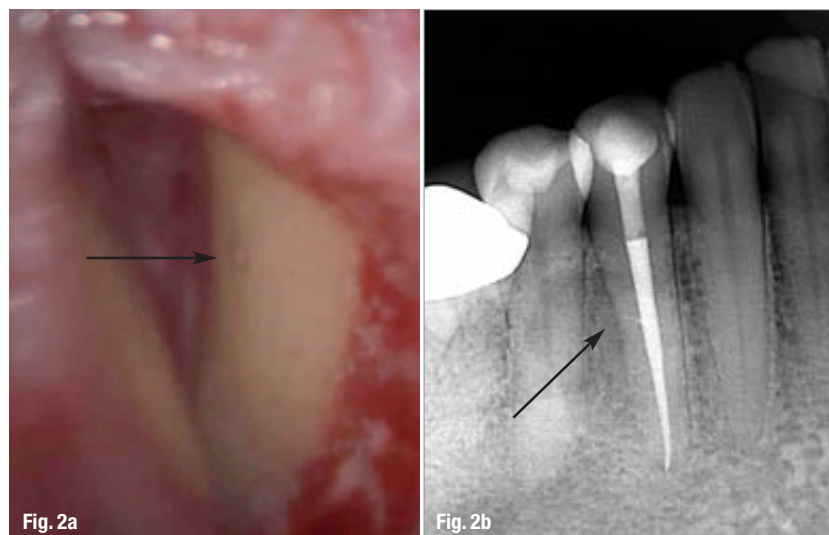
**Fig. 2b**\_The sealed upward-facing lateral can be seen on the post-op digital image.

\_Endodontics is currently experiencing an exciting period in its evolution: a period when progressive clinicians have become empowered to increase their rates of success owing to new technologies that enhance vision, disinfection and the protective seal of

the entire root-canal system. Early in my endodontic journey, Dr Herbert Schilder, a pioneering clinician, encouraged me to reach my full potential. We all aspire to reach our individual potential, and it is this collective pursuit of excellence that guides the future success of our specialty.

Our pursuit of higher success rates comes at a time of unique opportunity, a time when the comparative success rates between implants and endodontically treated teeth are being scrutinised<sup>1-2</sup>—and a time when some patients have been known to be advised to make decisions based mainly on a comparison of research-quoted technical success rates.

Dedicated clinicians are able to strive for improved success rates owing to many recent advances in our field. This article focuses on three areas of endodontics that have undergone profound advancement recently. The efficacy of our treatment has improved owing to our increased ability to visualise, disinfect and seal the entire root-canal system in three dimensions.

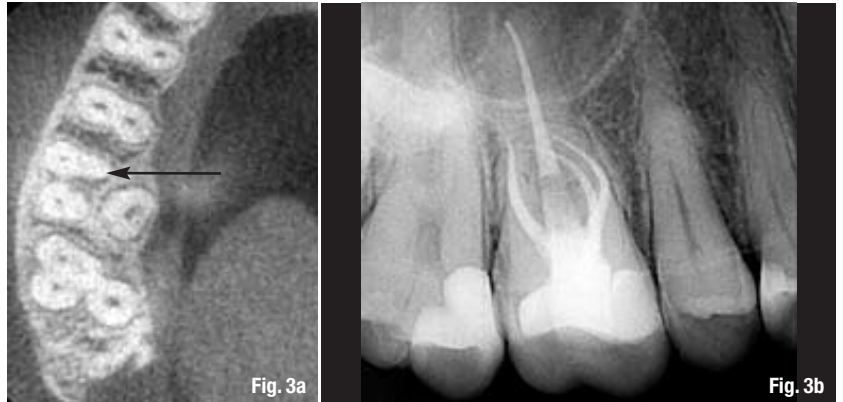

## —Precise 3-D visualisation

The ability to visualise the complexities of pulpal anatomy has had a tremendous impact on our ability to diagnose and treat complex endodontic disease.<sup>3-6</sup> For decades, the microscope has enhanced the quality of our endodontic treatment. The knowledge that greater expertise and quality outcomes can result from increased visualisation is self-evident. Currently, cone beam computed tomography (CBCT) allows us to visualise the intricacies of individual pulpal anatomy more clearly in 3-D.<sup>7</sup> CBCT uncovers details of anatomy in the pulpal system and bone prior to initiating treatment, which in turn guides diagnosis and contributes significantly to more predictable treatment.<sup>8-9</sup> The following cases illustrate examples of how CBCT can aid the clinician in endodontic diagnosis and treatment.

When a patient presents with swelling of the lower right vestibule, a comprehensive examination is performed, including a 2-D digital peri-apical radiograph. In this case, a mid-root, cystic-appearing, radiolucent lesion was noted without peri-apical involvement (Fig. 1a). Upon CBCT evaluation, a lateral portal of exit was visualised in the centre of this osseous defect, which aided in the diagnosis of a lesion of endodontic origin (Fig. 1b).<sup>10-11</sup> Once comprehensive pulpal testing had been completed, tooth #28 was confirmed to be non-vital.

After analysing the information provided by the CBCT image, the infected lateral system was more easily located and instrumented with the sharp J-curve of a stiff #15 hand file (Fig. 1c). Treatment was enhanced by directly instrumenting this aspect of the pulpal system, as we know that this increases disinfection.<sup>12</sup> After non-surgical treatment had been completed, surgical intervention was performed owing to the appearance and size of the lesion. When the radicular cyst (confirmed histologically) had been removed, the surgical microscope displayed the lateral portal of exit to be sealed with gutta-percha (Fig. 2a). In addition, the sealed upward-facing lateral system can be seen on the post-operative digital image (Fig. 2b).



Comprehensive treatment of the entire pulpal system dictates endodontic success.<sup>13</sup> Figures 3a and b illustrate the common challenge that arises as the result of a second mesio-buccal system (MB2) in upper molars. Once clinicians visualise whether complex pulpal anatomy is present with CBCT, they can confidently and conservatively locate it under the microscope. With utilisation of this new technology, incomplete endodontic therapy should be a thing of the past.

CBCT has a profound impact on our ability to locate and treat calcified pulpal systems.<sup>14</sup> Figure 4a illustrates a calcified molar in need of endodontic therapy. Upon initial microscopic treatment, difficulty in locating the mesio-lingual (ML) system was encountered. Calcium hydroxide was placed and a CBCT image was taken. The location of the elusive canal was visualised as being patent and at the level of the current conservative exploration, but 0.25 mm to the lingual (Fig. 4b). Upon microscopic re-entry into the case, the ML canal was conservatively located and comprehensive treatment was completed (Fig. 4c).

## —Relentless pursuit of complete disinfection

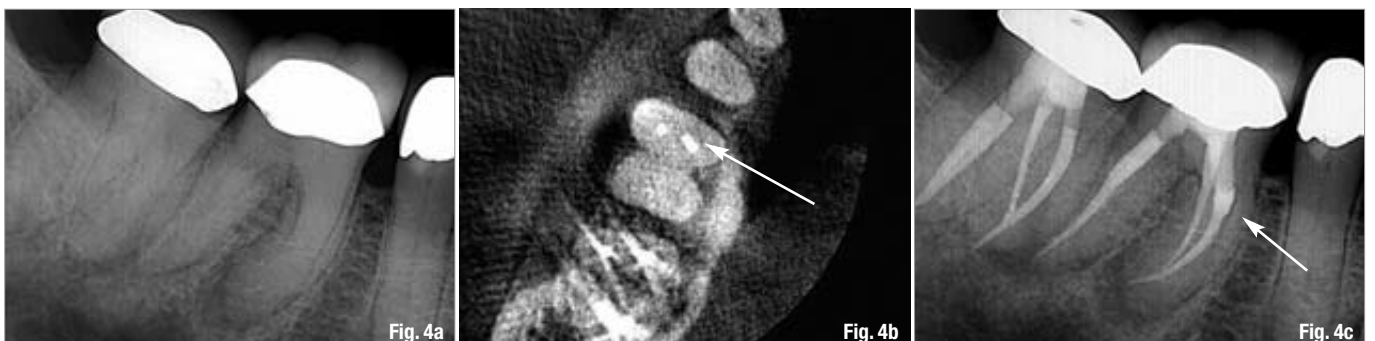Revolutionary advancements in endodontic disinfection have intensified our desire to reach higher levels of disinfection. One such device that facilitates this goal is the EndoVac (Discus Dental; Figs. 5a & b).<sup>15-17</sup> The EndoVac provides thorough irrigation of the complete root-canal system, including the critically

**Figs. 3a & b** CBCT technology is commonly used for confirmation of the presence and location of an MB2. This allows for confident, conservative and comprehensive treatment.

**Fig. 4a** A calcified molar in need of endodontic therapy.

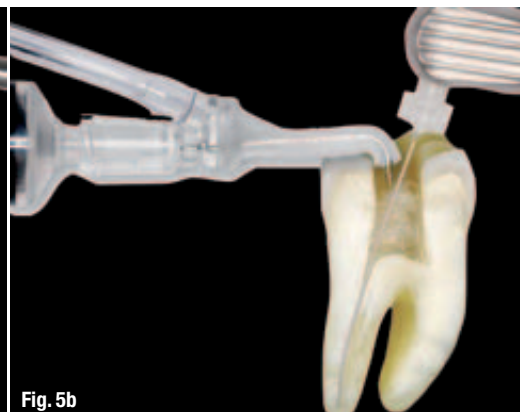
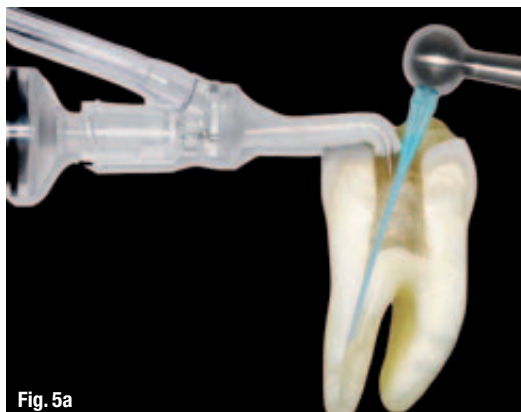**Fig. 4b** After initial exploration for the calcified ML system, calcium hydroxide was placed and a CBCT image was taken. The location of the elusive canal was visualised to be patent and at the level of the current conservative exploration, but 0.25 mm to the lingual.

**Fig. 4c** CBCT information allowed for the conservative location of the calcified ML system and completion of comprehensive treatment of the entire root-canal system.



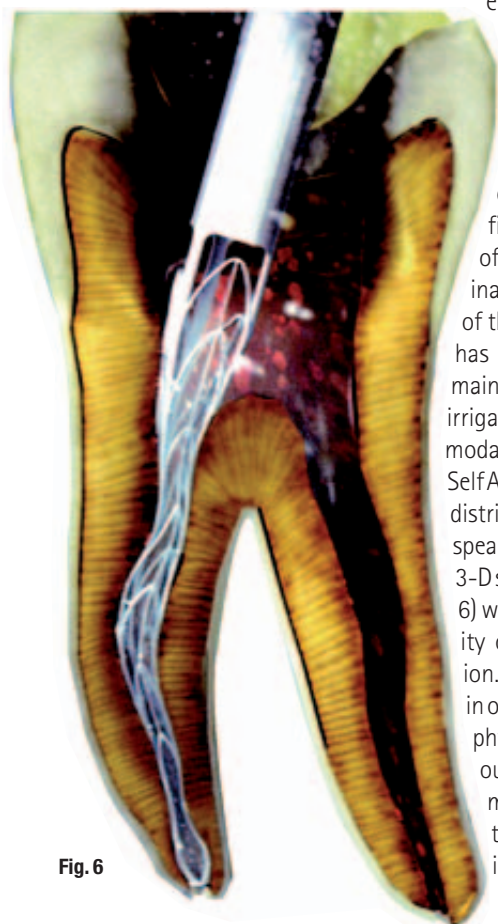
**Fig. 5a** MacroCannula aids in the removal of gross debris during treatment, especially in the mid-root to coronal areas.

**Fig. 5b** MicroCannula facilitates the removal of microscopic debris at the apical 1 mm of the root-canal system.



important apical region.<sup>18-22</sup> The device delivers the disinfecting solution to the coronal aspect of the pulpal system and draws the solution to the apical region of the pulpal system by way of evacuation. This technique allows for a safe, comprehensive irrigation of the entire root-canal system.<sup>23-25</sup> This technology overcomes the limitations of solution surface tensions and apical vapour locks that occur in deep, difficult-to-reach areas of pulpal systems.<sup>26</sup> In addition, the continuous movement of the solution increases microbial hydrolysis.<sup>27</sup>

**Fig. 6** SAF file offers us the ability to shape the morphology of individual pulpal systems in 3-D.



**Fig. 6**

In the pursuit to increase successful outcomes, the progressive clinician must stay at the forefront of new treatment modalities that may increase our efficacy in attaining higher levels of disinfection. Traditional endodontic techniques are based on the theory that files shape and irrigation solutions clean.<sup>28</sup> We know the limitations of current rotary files in shaping the morphology of complex root-canal systems. On average, most file systems reach less than 50% of canal walls.<sup>29</sup> Therefore, our inability to reach many surfaces of the root-canal system physically has dictated that disinfection rely mainly on the many techniques of irrigation. However, a new treatment modality challenges this method. The SelfAdjusting File Endodontic System distributed by Henry Schein, Inc., spearheads this new direction into 3-D shaping. The SAF instrument (Fig. 6) was designed to reach the majority of pulpal walls in a 3-D fashion.<sup>30-31</sup> This potential quantum leap in our ability to reach all pulpal walls physically, significantly increases our efficacy in disinfection.<sup>32</sup> This may set forth a paradigm shift in the way we approach our shaping and disinfecting techniques.

### Higher success rates with the 3-D seal of the entire root-canal system—advances in the coronal seal

Once the 3-D intricacies of a root-canal system have been evaluated, shaped and disinfected, then success ultimately lies in our ability to seal this complex and vulnerable system from the pathogenic source of endodontic disease, the oral cavity.<sup>33-34</sup> Overall endodontic success rates would be higher if all clinicians placed the coronal seal immediately after the canals are sealed. This is the time when the isolated pulpal system is at its highest level of disinfection. We know that endodontic disease emanates from the oral cavity and we strive to disinfect and seal the smallest of crevices within canal systems, but what about the main portal of entry for these pathogens? Figure 7 illustrates a lack of respect for this well-understood requirement for success. A relatively similar case treated in Figure 8 has a significantly increased overall prognosis.

In addition to common sense, the amount of quality research that supports this imperative final objective of successful endodontic treatment is staggering.<sup>35-43</sup> A recent, impressive study was performed by one of the largest insurance companies in the US in an effort to evaluate the success of endodontic outcomes. In assessing over 1.4 million endodontic cases over an eight-year period, they found a success rate of 97%. Pretty impressive! However, it was also found that in the 3% of cases that failed, 85% did not have coronal coverage.<sup>44</sup> Imagine the achievable success rate of modern endodontic therapy should an immediate seal of the entire root-canal system become the standard of practice.

Endodontists should diligently educate those in their local dental community of the overwhelming importance of this immediate final phase of successful root-canal therapy. A universal practice of placing the coronal seal as a final phase of treatment will greatly enhance the success of our profession. The prudent endodontic practitioner should exclude any

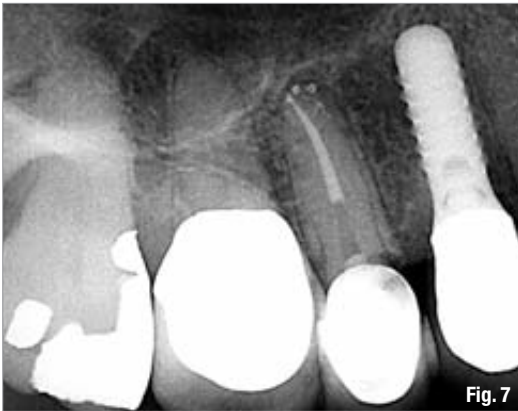

Fig. 7

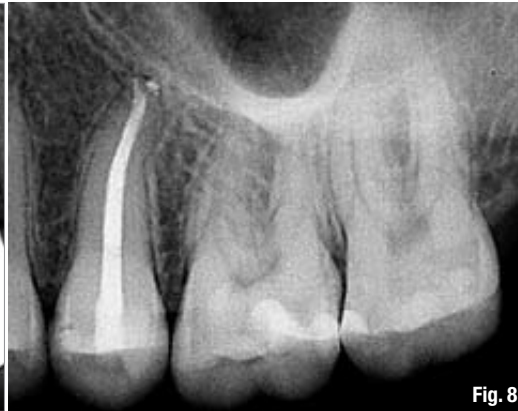

Fig. 8

**Fig. 7\_** This case illustrates a lack in respect for the need to place a proper coronal seal immediately after obturation.

**Fig. 8\_** This relatively similar case illustrates a significantly increased prognosis owing to the fulfilment of this final requirement for success.

knowledgeable clinician contributing to the patient's dental health, who does not respect this imperative objective for a successful outcome. Reasons for having a separate clinician complete the coronal seal at a later time are usually business related. These type of rationalisations do not adhere to our Hippocratic Oath to promote the best interests of the patient. Figures 9a and b illustrate the reproducible healing potential of lesions of endodontic origin when this final objective of successful endodontic therapy is accomplished.

The cornerstone of a successful coronal seal is the ability to obtain deep dentinal bonding. For accurate placement into deep, confined spaces, most-dual cured application tips can be augmented with a securely fastened etchant tip (Fig. 10). The etchant tip by Pulpdent (ref #22D100) works quite well in this regard. In order to maximise deep dentinal bonding, a dual-cured bonding agent should be used in conjunction with a dual-cured resin.<sup>45</sup> The typical sequence to attain maximum deep dentinal bonding after obturation is solvent, etchant, pre-bond, followed by the mixing of A and B. Owing to the compatibility of the materials, this older generation of bonding agents has been shown to have increased bond strength when used in conjunction with a dual-cured resin.<sup>45</sup>

In addition to providing the coronal seal of the root-canal system, deep dentinal bonding must also ensure the retention of the core. Each case should be individually assessed in this regard.

### The future of endodontics

Currently, many are in favour of alternatives to the retention of natural teeth through successful endodontic therapy. Not since the focal infection era have we seen such ill-advised loss of viable teeth. These opponents of endodontic therapy feel that the field is a dying profession. They speak of root-canal therapy as a holding pattern for an implant. Indeed, this statement may be true when the requirements for suc-

cessful treatment are not strictly adhered to. Fortunately, dedicated clinicians have never been equipped with so many tools to diagnose correctly and treat complex endodontic disease. The ability to provide endodontic excellence is more attainable today because of our ability to see, disinfect and seal the entire root-canal system in 3-D.

**Figs. 9a & b\_** Deep dentinal bonding was accomplished with a dual-cured resin to complete the final requirement of successful endodontic therapy.

**Fig. 10\_** Most dual-cured application tips can be augmented with a securely fastened etchant tip to allow for deep placement into confined spaces.

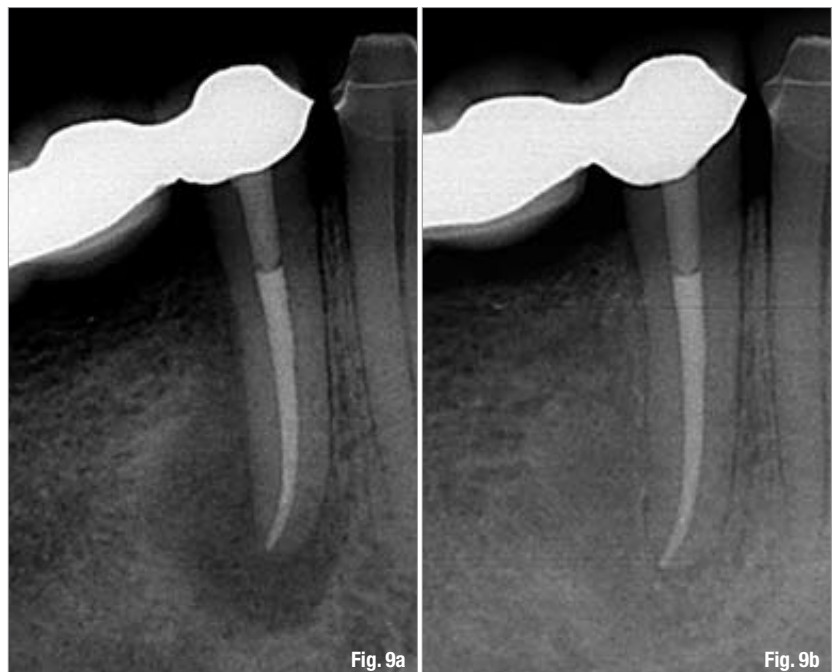

Fig. 9a

Fig. 9b

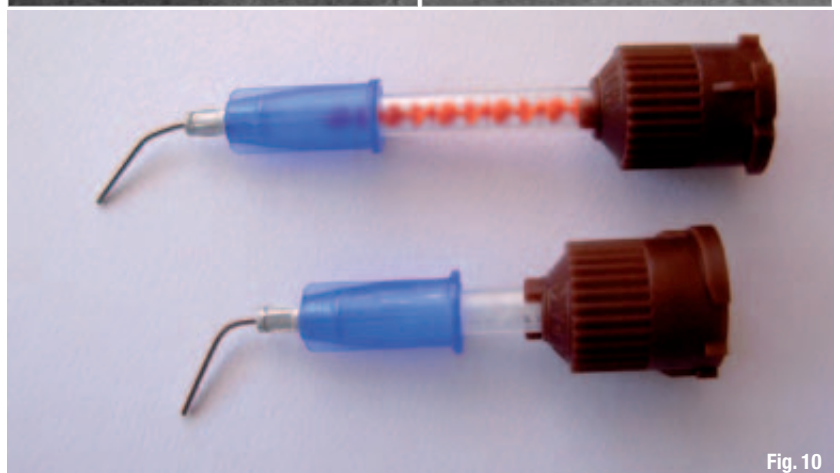

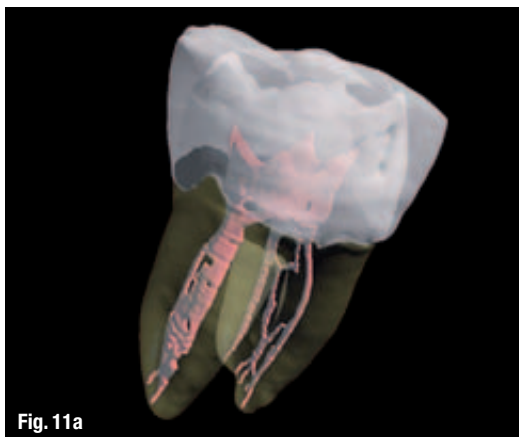Fig. 10

**Fig. 11a**\_Annotated 3-D model of a lower molar that illustrates complex pulpal anatomy.

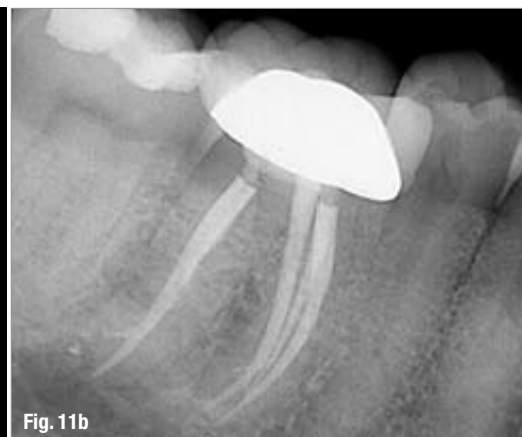**Fig. 11b**\_Endodontic therapy that illustrates the respect for the natural pulpal anatomy present.

**Fig. 12a**\_Post-op image of the ability to seal complicated pulpal anatomy.

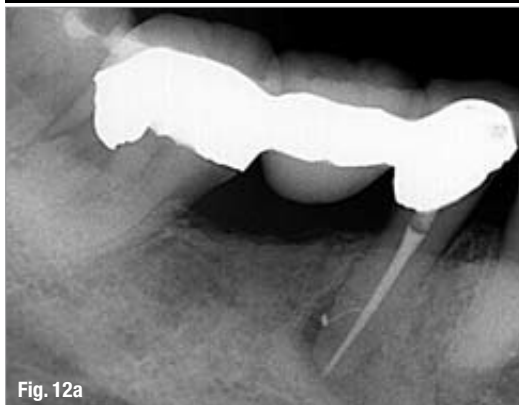**Fig. 12b**\_Healing observed when objectives for successful endodontic therapy are accomplished.



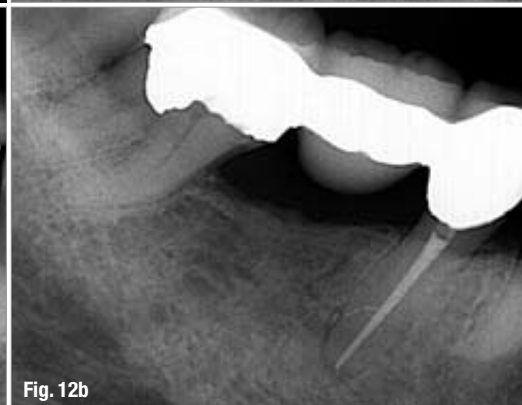
**Fig. 11a**



**Fig. 11b**



**Fig. 12a**



**Fig. 12b**

**Fig. 13**\_Illustration of the objective to have continual seal of the entire root-canal system from the apex to the cavo-surface.

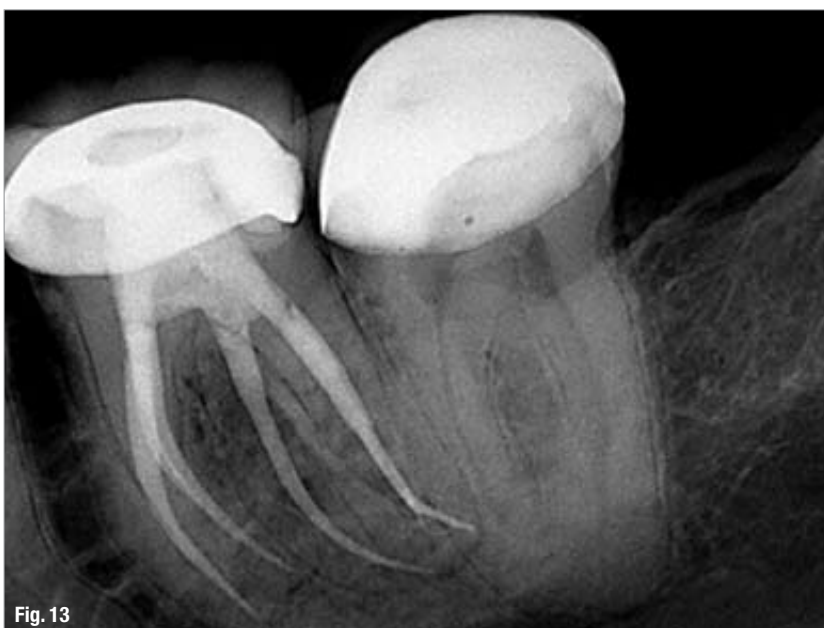Further advancement in our ability to visualise root-canal systems and the surrounding structures in 3-D will continue to revolutionise our capacity to diagnose and treat endodontic disease. The quality of endodontic therapy provided will increase as the science of CBCT develops. Future advancement in this science will focus on our ability to more clearly render and manipulate these images. Figure 11a is an annotated 3-D model of a lower molar that illustrates pul-

pal anatomy that is encountered in clinical practice.<sup>46</sup> Figure 11b displays the endodontic outcomes possible when such natural complexities are respected.

There are many exciting advancements on the horizon to aid in our pursuit of higher levels of disinfection. Further exploration into the potential to shape individual pulpal anatomy on a 3-D basis will continue. The science of irrigation may one day take us from disinfection to sterilisation. Figures 12a and b illustrate the successful outcome that can be accomplished when intricate areas of an infected root-canal system can be disinfected and sealed.

Future advancement in the pursuit of a precise coronal seal will be in the form of products and devices that aid in the technique-sensitive procedure of placing deep dentinal bonding. Figure 13 illustrates this objective of a continuous seal of the entire root-canal system from the apex to the cavo-surface.

These advances in endodontic treatment modalities will undoubtedly have a significant impact on our ability to attain greater success rates. However, the future of our profession is in the hands of skilled and committed clinicians who strive to move our profession forward. Progressive exploration into the areas discussed in this article will keep endodontic therapy at the forefront of treatment options available for patients.



**Fig. 13**

# implants

international magazine of oral implantology

## References

1. Doyle SL, Hodges JS, Pesun IJ, Baisden MK, Bowles WR. Factors affecting outcomes for single-tooth implants and endodontic restorations. *J Endod.* 2007 Apr;33(4):399–402.
2. Iqbal MK, Kim S. For teeth requiring endodontic treatment, what are the differences in outcomes of restored endodontically treated teeth compared to implant-supported restorations? *Int J Oral Maxillofac Implants.* 2007;22 Suppl: 96–116.
3. Estrela C, Bueno MR, Leles CR, Azevedo B, Azevedo JR. Accuracy of cone beam computed tomography and panoramic and periapical radiography for detection of apical periodontitis. *J Endod.* 2008 Mar;34(3):273–9.
4. Patel S, Dawood A, Mannocci F, Wilson R, Pitt Ford T. Detection of periapical bone defects in human jaws using cone beam computed tomography and intraoral radiography. *Int Endod J* 2009 Jun;42(6):507–15.
5. Tyndall DA, Rathore S. Cone-beam CT diagnostic applications: caries, periodontal bone assessment, and endodontic applications. *Dent Clin North Am.* 2008 Oct;52(4):825–41, vii.
6. Stavropoulos A, Wenzel A. Accuracy of cone beam dental CT, intraoral digital and conventional film radiography for the detection of periapical lesions. An ex vivo study in pig jaws. *Clin Oral Investig.* 2007 Mar;11(1):101–6.
7. Patel S. New dimensions in endodontic imaging: Part 2. Cone beam computed tomography. *Int Endod J.* 2009 Jun; 42(6): 463–75.
8. Low KM, Dula K, Bürgin W, von Arx T. Comparison of Periapical Radiography and Limited Cone-Beam Tomography in Posterior Maxillary Teeth Referred for Apical Surgery. *J Endod.* 2008;34(5):557–62.
9. Cotton TP, Geisler TM, Holden DT, Schwartz SA, Schindler WG. Endodontic applications of cone-beam volumetric tomography. *J Endod.* 2007 Sep;33(9):1121–32.
10. Schilder H. Filling root canals in three dimensions. *Dent Clin North Am.* 1967 Nov:723–44.
11. Schilder H. Canal debridement and disinfection. In *Pathways of the Pulp.* 1<sup>st</sup> Ed., St. Louis: Mosby Co., 1976:111–33.
12. Byström A, Sundqvist G. Bacteriologic evaluation of the efficacy of mechanical root canal instrumentation in endodontic therapy. *Scand J Dent Res.* 1981 Aug;89(4):321–8.
13. West JD. The relationship between three-dimensional endodontic seal and endodontic failure. Master Thesis. Boston: Boston University, 1975.
14. Matherne RP, Angelopoulos C, Kulild JC, Tira D. Use of cone-beam computed tomography to identify root canal systems in vitro. *J Endod.* 2008 Jan;34(1):87–9.
15. Hockett JL, Dommisch JK, Johnson JD, Cohenca N. Antimicrobial efficacy of two irrigation techniques in tapered and nontapered canal preparations: an in vitro study. *J Endod.* 2008 Nov;34(11):1374–7.
16. Brito PR, Souza LC, Machado de Oliveira JC, Alves FR, De-Deus G, Lopes HP, Siqueira JF Jr. Comparison of the effectiveness of three irrigation techniques in reducing intracanal *Enterococcus faecalis* populations: an in vitro study. *J Endod.* 2009 Oct;35(10):1422–7.
17. Miller TA, Baumgartner JC. Comparison of the antimicrobial efficacy of irrigation using the EndoVac to endodontic needle delivery. *J Endod.* 2010 Mar;36(3):509–11.



You can also subscribe via  
[www.oemus.com/abo](http://www.oemus.com/abo)

 **Subscribe now!**

I hereby agree to receive a free trial subscription of **implants international magazine of oral implantology** (4 issues per year). I would like to subscribe to **implants** for € 44 including shipping and VAT for German customers, € 46 including shipping and VAT for customers outside of Germany, unless a written cancellation is sent within 14 days of the receipt of the trial subscription. The subscription will be renewed automatically every year until a written cancellation is sent to OEMUS MEDIA AG, Holbeinstr. 29, 04229 Leipzig, Germany, six weeks prior to the renewal date.

▶ Reply via Fax +49 341 48474-290 to OEMUS MEDIA AG or per E-mail to: [grasse@oemus-media.de](mailto:grasse@oemus-media.de)

Last Name

First Name

Company

Street

ZIP/City/County

E-Mail

Signature

Notice of revocation: I am able to revoke the subscription within 14 days after my order by sending a written cancellation to OEMUS MEDIA AG, Holbeinstr. 29, 04229 Leipzig, Germany.

Unterschrift

18. Baumgartner JC, Falkler WA Jr. Bacteria in the apical 5 mm of infected root canals. *J Endod.* 1991 Aug;17(8):380–3.
19. Susin L, Parente JM, Loushine RJ, Ricucci D, Bryan T, Weller RN, Pashley DH, Tay FR. Canal and isthmus debridement efficacies of two irrigant agitation techniques in a closed system. *IEJ (In Press)*.
20. Parente JM, Loushine RJ, Susin L, Gu L, Looney SW, Weller RN, Pashley DH, Tay FR. Root canal debridement using manual dynamic agitation or the EndoVac for final irrigation in a closed system and an open system. *IEJ (In Press)*.
21. Nielsen BA, Baumgartner CJ. Comparison of the EndoVac System to Needle Irrigation of Root Canals. *J Endod* 2007; 33(5):611–5.
22. Shin SJ, Kim HK, Jung IY, Lee CY, Lee SJ, Kim E. Comparison of the cleaning efficacy of a new apical negative pressure irrigating system with conventional irrigation needles in the root canals. *Oral Surg Oral Med Oral Pathol Oral Radiol Endod.* 2010 Mar;109(3):479–84.
23. Desai P, Himel V. Comparative Safety of Various Intracanal Irrigation Systems. *J Endod* 2009;35:545–9.
24. Mitchell RP, Yang SE, Baumgartner JC. Comparison of apical extrusion of NaOCl using the EndoVac or needle irrigation of root canals. *J Endod.* 2010 Feb;36(2):338–41.
25. Gondim E Jr, Setzer FC, Dos Carmo CB, Kim S. Postoperative pain after the application of two different irrigation devices in a prospective randomized clinical trial. *J Endod.* 2010 Aug; 36(8):1295–301.
26. Tay FR, Gu LS, Schoeffel GJ, Wimmer C, Susin L, Zhang K, Arun SN, Kim J, Looney SW, Pashley DH. Effect of vapor lock on root canal debridement by using a side-vented needle for positive-pressure irrigant delivery. *J Endod.* 2010 Apr;36(4):745–50.
27. Clegg MS, Vertucci FJ, Walker C, Belanger M, Britto LR. The effect of exposure to irrigant solutions on apical dentin biofilms in vitro. *J Endod.* 2006 May;32(5):434–7.
28. Baker NA, Eleazer PD, Averbach RE, Seltzer S. Scanning electron microscopic study of the efficacy of various irrigating solutions. *J Endod.* 1975 Apr;1(4): 127–35.
29. Peters OA, Schönerberger K, Laib A. Effects of four Ni-Ti preparation techniques on root canal geometry assessed by micro computed tomography. *Int Endod J.* 2001 Apr; 34(3):221–30.
30. Metzger Z, Zary R, Cohen R, Teperovich E, Paqué F. The Quality of Root Canal Preparation and Root Canal Obturation in Canals Treated with Rotary versus Self-adjusting Files: A three-dimensional micro-computed Tomographic Study. *J Endod.* 2010 Sep;36(9):1569–73.
31. Peters OA, Boessler C, Paqué F. Root canal preparation with a novel nickel-titanium instrument evaluated with micro-computed tomography: canal surface preparation over time. *J Endod.* 2010 Jun;36(6):1068–72.
32. Metzger Z, Teperovich E, Cohen R, Zary R, Paqué F, Hülsmann M. The self-adjusting file (SAF). Part 3: removal of debris and smear layer-A scanning electron microscope study. *J Endod.* 2010 Apr;36(4):697–702.
33. Kakehashi S, Stanley HR, Fitzgerald RJ. The effects of surgical exposures of dental pulps in germfree and conventional laboratory rats. *J South Calif Dent Assoc.* 1966 Sep;34(9):449–51.
34. Möller AJ, Fabricius L, Dahlén G, Ohman AE, Heyden G. Influence on periapical tissues of indigenous oral bacteria and necrotic pulp tissue in monkeys. *Scand J Dent Res.* 1981 Dec; 89(6):475–84.
35. Southard DW. Immediate core build-up of endodontically treated teeth: the rest of the seal. *Pract Periodontics Aesthet Dent.* 1999 May;11(4):519–26; quiz 528.
36. Tronstad L, Asbjørnsen K, Døving L, Pedersen I, Eriksen HM. Influence of coronal restorations on the periapical health of endodontically treated teeth. *Endod Dent Traumatol.* 2000 Oct;16(5):218–21.
37. Helling I, Gorfil C, Slutzky H, Kopolovic K, Zalkind M, Slutzky-Goldberg I. Endodontic failure caused by inadequate restorative procedures: review and treatment recommendations. *J Prosthet Dent.* 2002 Jun;87(6):674–8.
38. Weine FS. In *Endodontic Therapy*. 5th Ed., St. Louis: Mosby Co., 1996:4.
39. Ray HA, Trope M. Periapical status of endodontically treated teeth in relation to the technical quality of the root filling and the coronal restoration. *Int Endod J.* 1995 Jan;28(1):12–8.
40. Torabinejad M, Ung B, Kettering JD. In vitro bacterial penetration of coronally unsealed endodontically treated teeth. *J Endod.* 1990 Dec;16(12):566–9.
41. Alves J, Walton R, Drake D. Coronal leakage: endotoxin penetration from mixed bacterial communities through obturated, post-prepared root canals. *J Endod.* 1998 Sep;24(9):587–91.
42. Ricucci D, Gröndahl K, Bergenholtz G. Periapical status of root-filled teeth exposed to the oral environment by loss of restoration or caries. *Oral Surg Oral Med Oral Pathol Oral Radiol Endod.* 2000 Sep;90(3):354–9.
43. Swanson K, Madison S. An evaluation of coronal microleakage in endodontically treated teeth. Part I. Time periods. *J Endod.* 1987 Feb;13(2):56–9.
44. Salehrabi R, Rotstein I. Endodontic treatment outcomes in a large patient population in the USA: an epidemiological study. *J Endod.* 2004 Dec;30(12):846–50.
45. Schwartz RS, Fransman R. Adhesive dentistry and endodontics: materials, clinical strategies and procedures for restoration of access cavities: a review. *J Endod.* 2005 Mar;31(3):151–65.
46. Brown WP, Herbranson EJ. Brown and Herbranson Imaging: [www.brownherbransson.com/tutorial\\_atlas.shtml](http://www.brownherbransson.com/tutorial_atlas.shtml).

*Editorial note: Dr Simons performed all treatments presented in this article. He does not currently have an interest in any products discussed in this article. All CBCT images were taken with the Kodak 9000 3D CBCT and all 2-D images were taken with the Kodak 6100.*

## \_about the author

## roots



**Dr Wyatt D. Simons** is a diplomate of the American Board of Endodontists. After graduating from the University of the Pacific, Arthur A. Dugoni School of Dentistry, in 1999, he completed his specialty training in endodontics at Boston University in 2001. Dr Simons is an Adjunct Assistant Professor of Endodontics at the University of the Pacific and lectures nationally. In 2004, he founded Signature Specialists in San Clemente, California, where he practises and presents live

training seminars. Dr Simons is passionately committed to the advancement of the profession of endodontics. Most recently, he presented live treatment to the American Association of Endodontists (AAE) as part of the Master Clinician Series at the 2010 AAE conference. To learn more about Dr Simons, go to [www.signatureendo.com](http://www.signatureendo.com).

